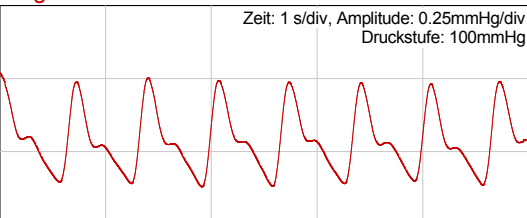
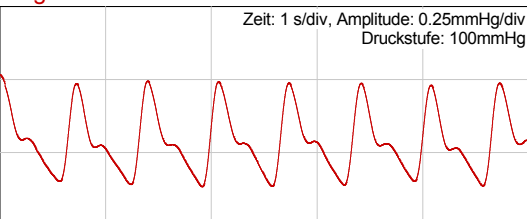


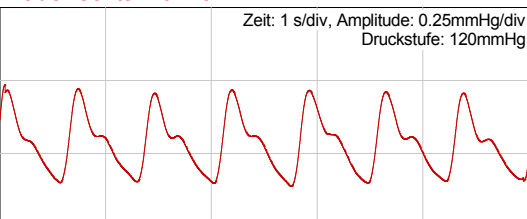
**Finger rechts: normal**



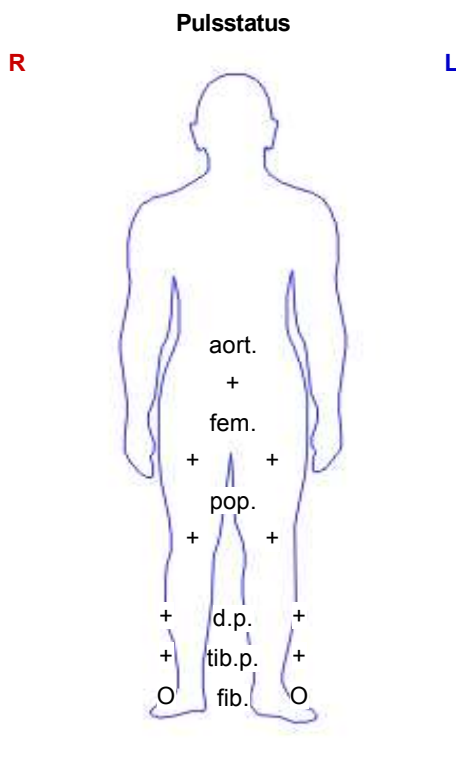

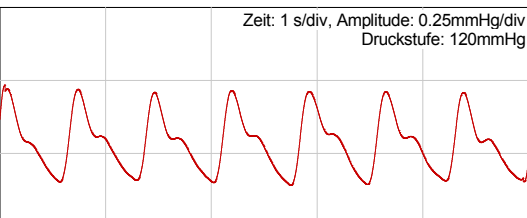
**Finger rechts: normal**



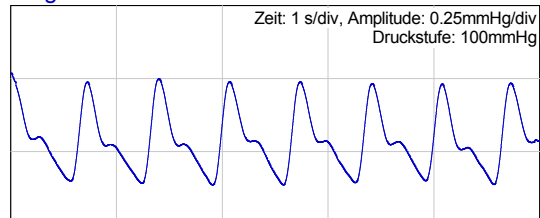
**Wade rechts: normal**



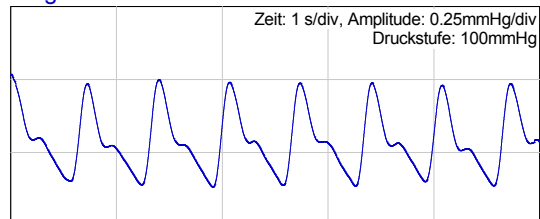
**Vorfuss rechts: normal**



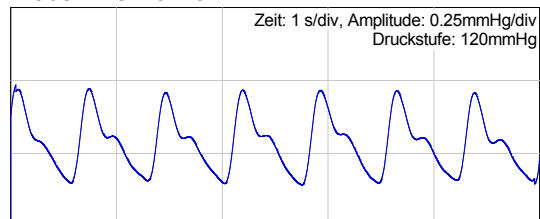
**Finger links: normal**



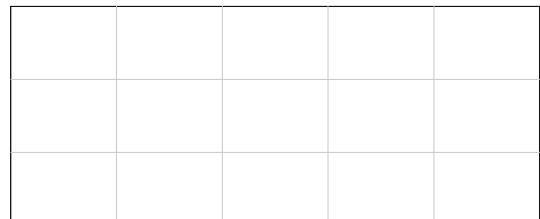
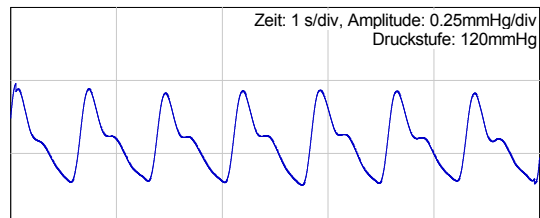
**Finger links: normal**



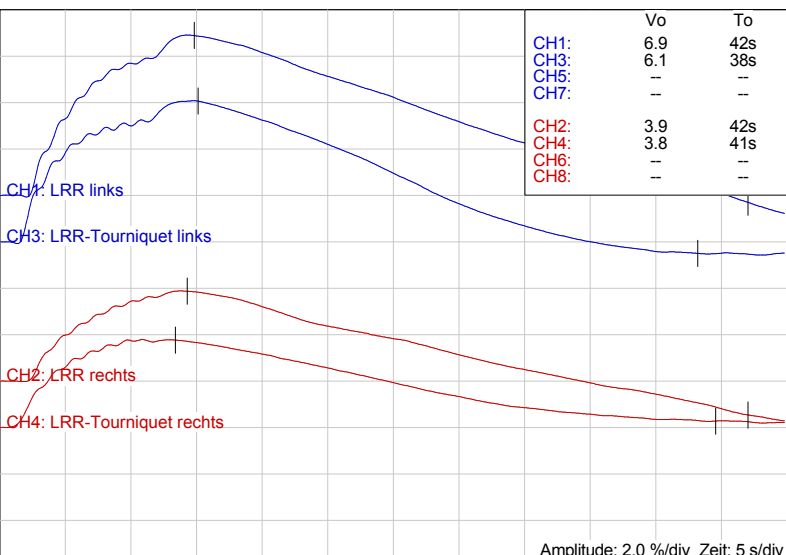
**Wade links: normal**



**Vorfuss links: normal**



Druckindizes		
R		L
--	A. Brachialis	--
1.18	A. Dorsalis Pedis	1.10
1.25	A. Tibialis Posterior	1.32
1.27	A. Fibularis	1.31
Systolischer Druck		
R		L
100	A. Brachialis	105
124	A. Dorsalis Pedis	115
131	A. Tibialis Posterior	139
133	A. Fibularis	138



**Kommentar:** Normalbefund

**Text:**  
Unauffälliger Befund

Starke Symmetrische Pulscurven  
Steiler pulsatiler Anstieg

Gute venöse Pumpleistung und Wiederauffüllzeiten